





REVIEW ARTICLE

Cellulite: Presentation and management

Gulhima Arora MD¹  | Anant Patil MD²  | Zahra Hooshanginezhad MD³ |
 Klaus Fritz MD^{4,5}  | Carmen Salavastru MD^{5,6} | Martin Kassir MD⁷ |
 Mitchel P Goldman MD^{8,9} | Michael H. Gold MD¹⁰  | Maurice Adatto MD¹¹ |
 Stephan Grabbe MD¹² | Mohamad Goldust MD¹³ 

¹Department of Dermatology, Mehektagul Dermaclinic, New Delhi, India

²Department of Pharmacology, Dr. DY Patil Medical College, Navi Mumbai, India

³Shiraz University of Medical Sciences, Shiraz, Iran

⁴Dermatology and Laser Center, Landau, Germany

⁵"Carol Davila" University of Medicine and Pharmacy, Bucharest, Romania

⁶Dermato-oncology Research Facility, Pediatric Dermatology Discipline, "Colentina" Clinical Hospital, Bucharest, Romania

⁷Worldwide laser institute, Dallas, Texas, USA

⁸Cosmetic Laser Dermatology: A West Dermatology Company, San Diego, California, USA

⁹Department of Dermatology, University of California, San Diego, California, USA

¹⁰Gold Skin Care Center, Tennessee Clinical Research Center, Nashville, Tennessee, USA

¹¹Skinpulse Dermatology and Laser Centre, Geneva, Switzerland

¹²Department of Dermatology, University Medical Center of the Johannes Gutenberg University, Mainz, Germany

¹³Department of Dermatology, University Medical Center Mainz, Mainz, Germany

Correspondence

Mohamad Goldust, Department of Dermatology, University Medical Center Mainz, Mainz, Germany.
 Email: mgoldust@uni-mainz.de

Funding information

Open Access funding enabled and organized by Projekt DEAL. WOA Institution: Johannes Gutenberg Universität Universitätsmedizin. Blended DEAL: Projekt DEAL.

Abstract

Background: Cellulite is a common dermatological condition with a female preponderance, affecting up to 90% post-pubertal females. It is characterized with dimpling and denting of the skin surface, giving it a Peau d'orange appearance. Once considered to be a benign physiological isolated skin condition of only an esthetic concern, cellulite is now considered a pathological entity with systemic associations and a negative psychological impact on patients.

Aims: The objective of this article was to discuss etiology, pathophysiology, and treatment of cellulite.

Materials and methods: Literature was screened to retrieve articles from PubMed/Medline and Google Scholar and related websites. Cross-references from the relevant articles were also considered for review. Review articles, clinical studies, systematic reviews, meta-analysis, and relevant information from selected websites were included.

Results: Several treatment options from lifestyle modifications and topical cosmetic therapies to energy-based devices have been studied for its treatment. However, treatment remains a challenge despite many new modalities in the armamentarium.

This is an open access article under the terms of the Creative Commons Attribution-NonCommercial License, which permits use, distribution and reproduction in any medium, provided the original work is properly cited and is not used for commercial purposes.

© 2022 The Authors. *Journal of Cosmetic Dermatology* published by Wiley Periodicals LLC

Laser and light therapies along with radiofrequency are useful treatment options with good safety profile. Acoustic wave therapy, subcision, and 1440-nm Nd:YAG minimally invasive laser are beneficial in cellulite reduction.

Discussion: Methodological differences in the trials conducted make it difficult to compare different treatment modalities.

Conclusion: Overall, treatment needs to be individualized based on the patient characteristics and severity of the condition. A combination of treatments is often required in most patients for reducing cellulite.

KEYWORDS

cellulite, management, presentation

1 | INTRODUCTION

Cellulite is a painless skin condition involving esthetic concerns with dimpling and denting of the skin surface, giving it an orange peel appearance. It is a common condition occurring in about 80%–90% of post-pubertal women of all races.¹ Almost all women think that they have cellulite at some time in their lives. It is seldom related to obesity, and methods of fat reduction do not work well for the condition. It occurs mostly in areas with greater fat storage like the thighs, buttocks, and abdomen.² It is also known as gynoid lipodystrophy, edematofibrosclerotic panniculopathy, or nodular liposclerosis.¹ The treatment remains a challenge, with several topical treatments, lifestyle modifications, non-invasive device-based treatments, intralesional and surgical modalities having been tried.

The term cellulite is a misnomer as it has no relation to cellulitis, nor is it derived from it. The “sense of cellulitis in cellulite is erroneous.”³ This was interestingly emphasized in the title of the same article “So-called cellulite: an invented disease.”³ Cellulite is also called gynoid lipodystrophy as it is mostly seen in areas of female fat distribution. This nomenclature points to it being associated with lipodystrophy.⁴

1.1 | Etiology and physiology of cellulite

The etiopathogenesis of cellulite still remains an enigma, but the dermis and the subcutaneous tissue are implicated alone or in combination.⁵ Obesity may worsen the condition.¹ Cellulite has been associated with estrogen and an increase in the estrogen levels accelerates its formation. Estrogen can be responsible for different steps implicated in the pathogenesis of cellulite.⁵

Menopause also worsens the condition due to increased vascular permeability and poor blood vessel tone. Dermal atrophy in the affected areas, the alteration in the subcutaneous septae, hypoxia, increased lipogenesis, and inflammation have all been postulated as contributory factors, and they may all be responsible together.

Men are rarely affected, and low androgen levels may be a causative factor.⁵ Low androgen levels in men seen in conditions such

as Klinefelter's syndrome, hypogonadism or after castration may contribute to the development of cellulite in them. Anti-androgen therapy for prostate cancer may also lead to cellulite.⁶

Genetic, environmental, and hormonal factors have been implicated in the development of cellulite. Caucasian race is more prone to develop it. Improper lifestyle is an important contributor for its acceleration of development.⁴ Alcohol stimulates lipogenesis, dehydration, and impaired storage of fat.⁴

1.2 | Newer insights into the mechanobiology of cellulite

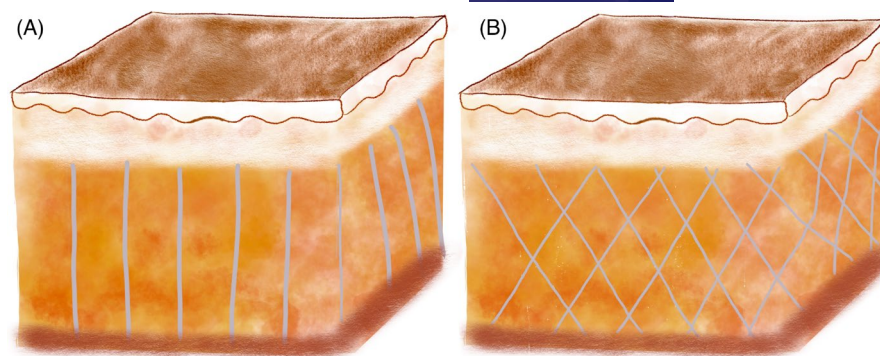
Initially considered to be a non-inflammatory skin condition, cellulite is now being recognized as a distinct pathologic entity with inflammation playing a key role.⁴

The concept of sex-typical differences in the skin of the thighs and buttocks was proposed as early as 1978 by Neurnberger and Muller. Deep biopsies from 150 cadavers and 30 live women with cellulite revealed that the dermis of the skin of males is thicker, with subcutaneous fat being present in polygonal sections rather than vertical standing units which are wider and taller in females. The fibrous septae separating the fat compartments criss-cross in males are oriented at approximately 45°, rather than being vertically present as in females (Figure 1). These findings suggest the female preponderance of cellulite by protrusion of subcutaneous fat called “papillae adiposae” through the thinned dermis as one of the pathogenetic pathways of developing cellulite.^{3,5}

These findings also explain the “mattress phenomenon” due to the “pinch test.” Cellulite exhibiting this is also known as “incipient cellulite,” where the dimpling occurs only on pinching the skin.⁷ Dimpling occurs on the surface of the female skin and just furrows on the male skin. The “mattress phenomenon” is not a cardinal sign of cellulite but denotes that it is due to the sex-typical skin structure and hence better termed “status protrusus cutis”.³

Aging also reduces thickness of the dermis by reducing the collagen and elastin thus making fat protrusion more into the dermis. The fat globules become more hypertrophied with age.³ This explains

FIGURE 1 cellulite



potential of cellulite occurrence more common with advancing age, but since dermis aging is seen in both genders, it may not be a primary contributor to its development.

Elderly women with higher body mass index are at higher risk for the development of cellulite.⁸ Cellulite can worsen in obese females,⁸ but can occur in lean women as well. However, magnetic resonance imaging (MRI) studies have shown a difference in the orientation, thickness, and even number of fibrous septae.⁷⁻⁹ These studies showed more abundant and sclerotic fibrous septae.¹⁰

Interestingly, there was no correlation between the presence of cellulite and fat herniations and the presence of “full-blown cellulite” occurring without pinching, the “incipient cellulite.” Both were due to tethering of the skin by the vertical fibrous strands, weakening the connective tissue thus causing the fat to herniate thus suggesting fat herniation is a secondary event.⁷

1.3 | Pathophysiology of cellulite

There are four hypotheses to explain the physiology of cellulite: sex-specific dimorphic skin structure, alteration in the fibrous septae of the subcutis, vascular factors, and inflammation.⁷

According to the vascular hypothesis, the precapillary arteriolar sphincter in the affected areas is altered. Moreover, deposition of altered, hyperpolymerized glycosaminoglycans (GAGs) causes pressure on the capillary walls with exudation of fluid in the spaces between the fat lobules and inter-lobular septae.⁷ Hypoxia and intercellular edema set the stage for fibrogenesis with increase in the number and thickness of the inter-lobular septae. Hypoxia also leads to resistance to lipolytic mechanisms and a low estrogenic state and high carbohydrate intake cause the fat globules to become more hypertrophied and nodular.¹¹ Endothelial damage is associated with presence of reactive oxygen species and the release of proinflammatory cytokines. Inflammation itself could be the cause of endothelial damage. When associated with obesity and insulin resistance, the presence of macrophages, Th1 cells, and mast cells can contribute to the blood vessel damage occurring in cellulite. Proinflammatory cytokines such as IL6 and TNF alpha are also associated with cardiovascular risk. Inflammation was proposed as a contributor to the development of cellulite due to presence of tenderness on pinching

the affected skin. According to Kligman, a low-grade septal inflammation is responsible for dermal atrophy.¹²

Hypoxia inducible factor 1 (HIF-1) protein is increased in cellulite. In a study, women with an allele polymorphism for HIF-1 did not develop cellulite or developed a mild form.¹³ Low levels of adiponectin and high levels of leptin have been implicated in the development of cellulite.⁴

1.4 | Histopathology of cellulite

At the microscopic level, there is a hypertrophy and dystrophy of the adipocyte structure, increased fibrosis of the interdigitating septae and enlargement and thickening of the vascular endothelium leading to microangiopathy.¹⁴ Septal inflammation may be observed. Later stages show atrophy and dystrophy of the skin, extensive vascular damage, and appendage disturbances. Noticeably, there may be a blurring of the border between the skin and the underlying tissue.

1.5 | Association with systemic disease

Cellulite is now considered to be more than just an esthetic problem.¹⁵ It is associated with negative psychological impact. With increasing insights into the pathogenesis, cellulite is now being considered as a systemic problem. There now seems to be a correlation between the stage of cellulite and the predisposition of systemic disease.⁴ Because of involvement of certain common pathological mechanisms, cellulite may be associated with insulin resistance, obesity, and increased cardiovascular risk.⁴ Hyperinsulinemia can accelerate lipodystrophy. There is a loss of the endocrinal functional ability of the dystrophic adipose tissue.⁴

2 | TREATMENT

Treatment of cellulite involves targeting various steps and pathways postulated in the etiopathogenesis. Although combination therapies have been tried, still there is no effective treatment.

2.1 | Lifestyle modification

This is an important step in genetically predisposed individuals and in preventing the worsening of cellulite. Excess weight can lead to more visible appearance of cellulite. In some people, reduction of body weight and maintaining it can be useful to reduce cellulite. A proper diet with low fat and sodium content, exercise and restricting smoking and alcohol are recommended^{16,17} for cellulite as well improvement of general health.

Exercise remains an important treatment for cellulite to prevent increase in amount of body fat. Regular exercise to maintain proper muscle mass should be advised to the patients. If texture of the skin is lost during weight loss, it may also make cellulite more visible. Therefore, aggravating factors for weight gain or excess weight loss should be avoided.

3 | ANTI-CELLULITE PRODUCTS

3.1 | Topical treatment

Topical preparations are mostly available as over the counter gels or creams. The main ingredients are caffeine, methylxanthines, retinol, ascorbic acid, alpha bisabolol, carica papaya extract, other plant extracts, vegetable oils, urea, and squalene.¹⁸ These therapies are postulated to work by causing decreased lipogenesis, improvement of microcirculation, increase in extracellular matrix synthesis and integrity, decreased inflammation and oxidation and increased lipolysis. Usually, multiple ingredients with different mechanisms of action are combined in a formulation. Caffeine is used in topical preparations because of its lipolytic property. However, there are limitations for use of caffeine, one of them being tendency to precipitate and result in clumps formation depending on the vehicle. There have been efforts to produce nanoemulsion containing caffeine with addition of surfactants for overcoming this challenge.¹⁹ According to the results of an animal study, emulsion with siloxanetriol alginate caffeine can promote the lipolytic action on fatty tissue whereas sodium benzoate addition to the preparations can inhibit efficiency of caffeine.²⁰ Formulation developments thus may play a role in efficacy of topical caffeine containing formulations. In another study, efficacy of extract of *Trichilia catigua* and *Ptychopetalum olacoides* Benthham applied once daily for 2 months was examined in 27 women between 20 and 40 years of age with moderate cellulite. There was significant reduction in the circumference of specific body areas. This therapy is expected to work by causing reduction in edema and improvement of local microcirculation.²¹

A sugar-derivative sulfo-carrabiose in a 3% cream applied twice a day for 8 weeks showed an improvement in cellulite.²² However, a study reported that improvements with topical agents were short lived, less than 2 weeks.²³ Thai herbal formulations have also been tried and shown to improve cellulite in a double-blind randomized trial.²³ In a double-blind, placebo-controlled, randomized study, involving 44 females between the age of 25–55 years with

mild–moderate cellulite, 81% claimed an improvement in their cellulite based on a questionnaire versus 32% of the placebo group.¹⁸ A systematic evaluation of the scientific evidence of the efficacy of topical cosmetic products in cellulite reduction concluded that they had a moderate efficacy in thigh circumference reduction. This review included 21 original studies, mostly including women. However, only 7 controlled trials were included for meta-analysis. The included studies had significant heterogeneity. The active ingredients in these preparations included one of the three components xanthenes, herbal components or retinoids or complex formulations, mostly containing xanthenes.²⁴ More evidence from larger multicentric controlled clinical trials is required for establishing specific topical formulation for the treatment of cellulite.

4 | ORAL SUPPLEMENTS

A questionnaire-based study concluded that women below the age of 55 years are the most common consumers of anti-cellulite products. According to this study, use of topical products scored over the use of oral supplements which carry more of a risk to benefit ratio.²⁵ Among the oral supplements, oral collagen has been tried for cellulite.²⁶ In a double-blind, placebo-controlled study involving 105 women, 2.5 g of the collagen peptide given over a period of 6 months resulted in significant reduction in cellulite as compared to the placebo group.²⁷

4.1 | Massage

Endermologie is a US FDA-approved treatment for the treatment of cellulite. It involves mechanical massage with an apparatus by creating positive and negative pressure. The LPG endermologie system uses positive pressure from two rollers and negative pressure from aspiration from the skin and subcutaneous tissue. An observational study using 15 sessions of 30–45 min each twice a week showed significant improvement; however, there was no information on the durability of results.⁵ In a study, it was only partially better than aminophylline topical cream.²⁸ This works on the principle of physical decongestion with lymphatic drainage and improving extracellular fluid.²⁹

4.2 | Subcision

It is recommended for cellulite depressions occurring at rest. Subcision involves the breaking of bands that tether the reticular dermis to the subcutaneous fat, thus improving the skin topography and redistribute subcutaneous tension forces. It also helps to push the fat lobules into spaces created by the subcision.^{1,30} Subcision may be manual, vacuum-assisted, or laser-assisted. Percutaneous infiltration of tumescent fluid is done, which not only creates a plane for subcision by elevating the subcutaneous tissue from the

underlying vital structures, but also anesthetizes the area.¹ Manual subcision is performed using a forked cannula or an 18-G needle, maintaining a correct depth of about 10–20 mm.³⁰ The potential inconsistency of performing subcision with a manual method led to the use of a vacuum-assisted device which has a more-controlled depth of inserting the subcision blade and better control of the tumescent anesthesia.^{1,31}

4.3 | Extracorporeal shock wave therapy

Acoustic waves are used to improve neocollagenesis, microcirculation, and lymphatic drainage.³² Initial mechanical stimulus by the pressure peak leads to matrix mobilization of cells by mechanotransduction of the signal. The shock wave cavitation following this causes mechanical disruption of cellulite and localized adiposities helps restructure the skin,^{33,34} and improves the cellulite outcome by inducing collagen remodeling. Low doses of 0.018 mJ/mm² to a depth of 5 mm administered over 4 cm squares with 100 shots per square³³ as well higher doses of 0.25 mJ/mm² to the underlying muscle have been described.³⁵ Overall focused and radial ECSW therapy devices have been found useful, albeit with a latency of 2–6 months.³⁵

Thus, some evidence for potential benefit is seen with acoustic wave therapy,³⁶ but several treatment sessions are required to see the visible reduction.

4.4 | Radiofrequency

Radiofrequency (RF) is one of the most frequently used energies in medicine and particularly in the esthetics medicine. The radiofrequency types to be distinguished are unipolar, monopolar, bipolar, and multipolar RF. However, its selective application is a novel approach. If superficial skin layers are cooled at the same time for protection, RF can even penetrate to the deeper fat tissue and there lead to apoptosis and thus fat cell degradation and circumference reduction.^{37–39}

The effect of the RF treatment depends on the combination of parameters such as energy density, exposure time, polarity of the radio frequency, surface cooling, and the method of application.^{40,41}

Multipolar selective radiofrequency is achieved by combining multiple plus and minus poles in a single applicator. Here, the energy of the radiofrequency emitted is selectively accumulated in the fat, which means selectivity of the storage capacity and conductivity of the fat. The energy is selectively delivered to the adipose tissue through contactless applicator and then transformed into heat. This selectiveness relies on the impedance difference between fat and other tissues, led by the respective absence and presence of water. The aimed process to be provoked is the apoptosis of fat cells. This can be applied to abdomen and upper thighs and shows a considerable reduction in circumference.⁴²

Monopolar and multipolar RF have a greater depth of penetration compared to bipolar RF. It works on the principle of bioimpedance.¹

Electrothermal effects are responsible for the denaturation of collagen, neocollagenesis, and skin tightening.^{5,33} It has been used in combination with pulsed magnetic therapy and dynamic muscle activation.^{2,43} A study evaluated effects of radiofrequency and dynamic muscle activation in treatment of abdominal cellulite in 25 females. Six weekly radiofrequency and dynamic muscle activation treatments resulted in significant reduction in abdominal circumference at 1- and 4-week follow-ups. Satisfaction with treatment outcome was reported by 92% patients.²

In another study, non-invasive cellulite treatments based on simultaneous application of monopolar RF and targeted pressure energy evaluated the application in women with cellulite. The results showed that this application is effective and safe for treating cellulite. The level of clinical improvement after four sessions is comparable to results reported after 6–20 sessions in studies on stand-alone RF/laser/targeted pressure energy devices, however, needs less devices, less time per treatment, and less sessions.⁴⁴ Limitations of radiofrequency include short lived results and need for several treatment sessions. Bruises can be seen after treatment with radiofrequency, which disappear with course of time.

5 | LASER AND LIGHT DEVICES

Laser energy penetrates the dermis or subcutaneous tissue depending on their wavelength. Local heating of tissue causes collagen remodeling and improves the microcirculation. Earlier use of intense pulse light, 810 nm diode laser alone or in combination with massage, vacuum and ultrasound were not conclusive.^{45,46} In a double-blind, placebo-controlled randomized trial involving 68 patients, 532 nm diode using 17 mW output has been reported to be effective without combination with other modalities.⁴⁷ Low-level laser therapy was effective in reducing at least one stage on the Nurnberger-Muller grading scale in 55.88% patients versus 8.82% in sham-treated group ($p < 0.0001$).⁴⁷ A multicenter study involving 37 patients using a three step procedure with 1440 Nd:YAG minimally invasive side-firing fiber at 8–10 W showed sustainable improvement in the appearance of cellulite for at least 1 year.⁴⁸ The procedure resulted in high satisfaction score for both the physician and patient. This modality has been reported to be most promising in laser and light devices.⁴⁹ Thus, some evidence for potential benefit is seen with 1440 nm Nd:YAG minimally invasive laser.³⁶ Overall, an important challenge for assessing the strength of evidence is methodological issues in the studies with laser- and light-based modalities and radiofrequency.

6 | DERMAL FILLERS

Calcium hydroxyapatite and poly-L-lactic acid (PLLA) are used to smoothen the skin in patients with cellulite.⁴⁹ It also helps to increase dermal thickness to make it harder for fat to dimple through the skin. Calcium hydroxyapatite in dilutions of 1:1 to 1:4 (1.5–6 ml

of diluent) injected using the canula or needles in radial, Asterix, or linear threading technique reported notable reductions in skin flaccidity and increase in skin density and thickness of the abdominal skin after only one session.^{50,51} PLLA is bio stimulatory filler that stimulates body's own collagen production thus also tightening the skin. It has been used in dilutions of 8–20 ml, with a good response at 12 ml dilution combined with subcision. A study involving 24 patients combined with Subcision reported persistent improvement in a 2-year follow-up. There was no occurrence of nodules or granulomas in the patients treated with subcision plus PLLA.⁵²

6.1 | Collagenase clostridium histolyticum

Collagenase clostridium histolyticum (CCH) is approved by the US FDA for the treatment of collagen-associated disorders like Peyronie's disease and Dupuytren's contracture. CCH hydrolyzes collagen under physiologic conditions and is composed up of two purified collagenases known as AUX-1 and AUX-II. Its acts on the fibrous septae involved in the development of cellulite.⁵³ In an open-label extension of a previous phase 2 randomized controlled trials, women with moderate-to-severe cellulite were subcutaneously administered CCH 0.84 mg in three treatment sessions perpendicular and at 45° angle to the skin in 0.1-ml aliquots. Improvements were observed to last through 2-year follow-up.^{54,55}

Qwo™ (CCH-aaes) is approved by the FDA for the treatment of moderate-to-severe cellulite in the buttocks of adult women.⁵⁶

6.2 | Ultrasound

High-frequency sound waves which deliver acoustic energy to increase tissue shrinkage, induce collagenosis and neolastogenesis have been in use for body sculpting. Superficial dermis is heated to 60–70°C, resulting in thermal tissue coagulation (1 mm³), activating the wound healing cascade, collagen contraction creating short and thick fibrils, and production of new collagen.⁵⁷ Microfocused ultrasound results in thermal injury zones up to a depth of 7–8 mm in the musculoaponeurotic layer sparing superficial epidermis, while high intensity focused ultrasound (HIFU) can target depths of 13 mm essential for abdominal cellulite. HIFU cavitation results in architectural changes in the subcutaneous fat tissue, disrupting the cellulite structure and smoothens dimpling.⁵⁸ HIFU can be used for tightening and recently also for fat reduction. Focused ultrasound is able to heat tissue up to 65–70°C in small microscopic areas. HIFU can penetrate much deeper with high energy than other techniques. The penetration depth into the tissue depends on the wavelength, the higher the frequency, the more superficial the effect. Using the new handpieces of 6, 9 mm, or recently 13 mm penetration depth, effects can be obtained in the fatty tissue which lead to circumferential reduction and tightening. HIFU treatment effectively reduced abdominal fat in a porcine model; it accurately treated the target subcutaneous

fat layer, and the subcutaneous fat was reduced effectively via ultrasonic measurement after HIFU treatment. Macrofocused ultrasound was successfully used for body contouring and fat reduction in pre-clinical and clinical studies.^{41,59,60}

High-frequency ultrasound in combination with vacuum drainage, suction, and massage have shown mild improvement in abdominal cellulite.^{58,61} In an open-label study, 28 patients underwent weekly transdermal focused ultrasonic lipolysis and vacuum drainage for a maximum of eight sessions. Significant reduction in circumference of abdominal girth was seen with ultrasonic lipolysis.⁶¹ Compared to radiofrequency, induction of both neocollagenosis and neolastogenesis appears to be an added advantage.⁶² Combination of both modalities showed improvement in abdominal cellulite.⁶³ Overall, there is no strong evidence to suggest that ultrasound alone can be significantly reduce cellulite. Combination with other treatment can decrease cellulite appearance. More evidence is required for demonstrating its efficacy in reduction of cellulite.

6.3 | Carboxytherapy

Transcutaneous administration of carbon dioxide by inducing a shift in oxygen dissociation curve to the right and vasodilatation induces neovascularization. In a study, two sessions per week with infused fixed volume of 250 ml of CO₂ per 100 cm² of treated surface of abdomen showed an objective change in morphology of adipocytes on histopathology with no change observed in the body mass index or body weight.⁶⁴

Intravenous bolus injections and continuous flow of 20–30 ml/s can also be used safely without hypercapnia or any other side effects with mild pain and aches.^{64–66} In a study involving 48 females with cellulite at thighs, subcutaneous infusion of six sessions at weekly interval has been shown to be as effective in cellulite and localized adiposities as mesolipolysis. In this study, follow-up was done for 6 months showed significant reduction in thigh circumference and cellulite grading scale.⁶⁷ Some patients may have discomfort during the treatment. In some patients, temporary bruising may also be seen.

6.4 | Other newer treatment

Resonic™ is an FDA-approved device for cellulite which works with rapid acoustic pulse technology. This is a non-invasive treatment which can reduce dimple and improves the cellulite appearance. The results are seen after one treatment session lasting for less than a hour.⁶⁸ The results may persist for 3 months.

Treatment needs to be individualized based on the patient characteristics and severity of the condition. Exercise should be recommended to all patients with cellulite. For mild-to-moderate cases, topical preparations may be tried first.

7 | CONCLUSION

This review summarizes the present pathophysiological understanding of cellulite. Suggested treatment options include lifestyle modification, topical preparations which reduce lipogenesis, improve microcirculation, increase extracellular matrix synthesis and integrity, and increase lipolysis, oral collagen peptide massage, subcision, extracorporeal shock wave therapy, radiofrequency, laser and light devices, dermal fillers, collagenase clostridium histolyticum, ultrasound, and carboxytherapy. Combination treatment is useful. Further research may refine the treatment algorithm and approach to its management; however, a combination approach remains the best way forward.^{69,70}

ACKNOWLEDGMENT

Open access funding enabled and organized by ProjektDEAL.

CONFLICT OF INTEREST

None.

AUTHOR CONTRIBUTIONS

Gulhima Arora involved in writing and revising the manuscript. Anant Patil, Michael H. Gold, Maurice Adatto, Stephan Grabbe, Mitchel P Goldman, Martin Kassir, Carmen Salavastru, Klaus Fritz, and Zahra Hooshanginezhad involved in review and revising the manuscript. Mohamad Goldust involved in conception, writing, review, and revising the manuscript.

ETHICAL APPROVAL

Not applicable, as this is a review article and not an original article. It does not involve any human/animal participation.

DISCLAIMER

"We confirm that the manuscript has been read and approved by all the authors, that the requirements for authorship as stated earlier in this document have been met and that each author believes that the manuscript represents honest work".

DATA AVAILABILITY STATEMENT

Data sharing is not applicable to this article as no new data were created or analyzed in this study.

ORCID

Gulhima Arora  <https://orcid.org/0000-0002-8365-3124>

Anant Patil  <https://orcid.org/0000-0002-9455-4025>

Klaus Fritz  <https://orcid.org/0000-0001-6225-4653>

Michael H. Gold  <https://orcid.org/0000-0002-5183-5433>

Mohamad Goldust  <https://orcid.org/0000-0002-8646-1179>

REFERENCES

1. Friedmann D, Vick G, Mishra V. Cellulite: a review with a focus on subcision. *Clin Cosmet Invest Dermatol*. 2017;10:17-23.

2. Wanitphakdeedecha R, Iamphonrat T, Thanomkitti K, Lektrakul N, Manuskiatti W. Treatment of abdominal cellulite and circumference reduction with radiofrequency and dynamic muscle activation. *J Cosmet Laser Ther*. 2015;17:246-251.
3. Nürnberger F, Müller G. So-called cellulite: an invented disease. *J Dermatol Surg Oncol*. 1978;4:221-229.
4. Tokarska K, Tokarski S, Woźniacka A, Sysa-Jędrzejowska A, Bogaczewicz J. Cellulite: a cosmetic or systemic issue? Contemporary views on the etiopathogenesis of cellulite. *Postepy Dermatol Alergol*. 2018;35:442-446.
5. Bass LS, Kaminer MS. Insights into the pathophysiology of cellulite: a review. *Dermatol Surg*. 2020;46:S77-S85.
6. Leszko M. Cellulite in menopause. *Menopausal Rev*. 2014;5:297-304.
7. Avram MM. Cellulite: a review of its physiology and treatment. *J Cosmet Laser Ther*. 2004;6:181-185.
8. Mirrashed F, Sharp JC, Krause V, Morgan J, Tomanek B. Pilot study of dermal and subcutaneous fat structures by MRI in individuals who differ in gender, BMI, and cellulite grading. *Skin Res Technol*. 2004;10:161-168.
9. Rudolph C, Hladik C, Hamade H, et al. Structural gender dimorphism and the biomechanics of the gluteal subcutaneous tissue: implications for the pathophysiology of cellulite. *Plast Reconstr Surg*. 2019;143:1077-1086.
10. Hexsel DM, Abreu M, Rodrigues TC, Soirefmann M, Do prado DZ, Gamboa MML. Side-by-side comparison of areas with and without cellulite depressions using magnetic resonance imaging. *Dermatol Surg*. 2009;35:1471-1477.
11. Janda K, Tomikowska A. [Cellulite - causes, prevention, treatment]. *Ann Acad Med Stetin*. 2014;60:29-38.
12. Kligman AM. Cellulite: facts and fiction. *J Geriatric Dermatol*. 1997;5:136-139.
13. Tomczyk M, Nowak W, Jaźwa A. [Endothelium in physiology and pathogenesis of diseases]. *Postepy Biochem*. 2013;59:357-364.
14. Quatresooz P, Xhauffaire-Uhoda E, Pierard-Franchimont C, Pierard GE. Cellulite histopathology and related mechanobiology. *Int J Cosmet Sci*. 2006;28:207-210.
15. Hexsel D, Weber MB, Taborda ML, Dal'Forno T, Prado DZ. A quality of life measurement for patients with cellulite. *Surg Cosmet Dermatol*. 2011;3:96-101.
16. Taati B, Khoshnoodnasab M. Exercise-based approaches to the treatment of cellulite. *Int J Med Rev*. 2019;6:26-27.
17. Löberbauer-Purer E, Meyer NL, Ring-Dimitriou S, Haudum J, Kässmann H, Müller E. Can alternating lower body negative and positive pressure during exercise alter regional body fat distribution or skin appearance? *Eur J Appl Physiol*. 2012;112:1861-1871.
18. Dupont E, Journet M, Oula M-L, et al. An integral topical gel for cellulite reduction: results from a double-blind, randomized, placebo-controlled evaluation of efficacy. *Clin Cosmet Invest Dermatol*. 2014;7:73-88.
19. Freire TB, Dario MF, Mendes OG, et al. Nanoemulsion containing caffeine for cellulite treatment: characterization and in vitro evaluation. *Braz J Pharm Sci*. 2019;55:e18236.
20. Velasco MVR, Tano CTN, Machado-Santelli CM, Consiglieri VO, Kaneko TM, Baby AR. Effects of caffeine and siloxanetriol alginate caffeine, as anticellulite agents, on fatty tissue: histological evaluation. *J Cosmet Dermatol*. 2008;7:23-29.
21. Velasco M, dos Santos IMNSR, Freire TB, Baby AR. Anticellulite efficacy of *Trichilia catigua* and *Ptychopetalum olacoides* Benth extracts; Eficácia anticelulite de extratos de *Trichilia catigua* e *Ptychopetalum olacoides* Benth. *Biology*. 2017. doi:10.19277/BBR.14.1.1492017
22. Vogelgesang B, Bonnet I, Godard N, Sohm B, Perrier E. In vitro and in vivo efficacy of sulfo-carrabiose, a sugar-based cosmetic ingredient with anti-cellulite properties. *Int J Cosmet Sci*. 2011;33:120-125.

23. Ngamdokmai N, Waranuch N, Chootip K, Jampachaisri K, Scholfield CN, Ingkaninan K. Cellulite reduction by modified Thai herbal compresses; a randomized double-blind trial. *J Evid-Based Integr Med*. 2018;23:2515690X18794158.
24. Turati F, Pelucchi C, Marzatico F, et al. Efficacy of cosmetic products in cellulite reduction: systematic review and meta-analysis. *J Eur Acad Dermatol Venereol*. 2014;28:1-15.
25. Contente B, Fernandes AI. A snapshot of anti-cellulite products' consumption and pharmaceutical intervention. *Ann Med*. 2019;51:85-85.
26. Choi FD, Sung CT, Juhasz MLW, Mesinkovsk NA. Oral collagen supplementation: a systematic review of dermatological applications. *J Drugs Dermatol*. 2019;18:9-16.
27. Schunck M, Zague V, Oesser S, Proksch E. Dietary supplementation with specific collagen peptides has a body mass index-dependent beneficial effect on cellulite morphology. *J Med Food*. 2015;18:1340-1348.
28. Collis N, Elliot LA, Sharpe C, Sharpe DT. Cellulite treatment: a myth or reality: a prospective randomized, controlled trial of two therapies, endermologie and aminophylline cream. *Plast Reconstr Surg*. 1999;104:1110-4; discussion 1115-1117.
29. Chang P, Wiseman J, Jacoby T, Salisbury AV, Ersek RA. Noninvasive mechanical body contouring: (Endermologie) a one-year clinical outcome study update. *Aesthetic Plast Surg*. 1998;22:145-153.
30. Hessel DM, Mazzuco R. Subcision: a treatment for cellulite. *Int J Dermatol*. 2000;39:539-544.
31. Green JB, Cohen JL. Cellfina observations: pearls and pitfalls. *Semin Cutan Med Surg*. 2015;34:144-146.
32. Adatto M, Adatto-Neilson R, Servant J-J, Vester J, Novak P, Krotz A. Controlled, randomized study evaluating the effects of treating cellulite with AWT/EPAT. *J Cosmet Laser Ther*. 2010;12:176-182.
33. Angehrn F, Kuhn C, Voss A. Can cellulite be treated with low-energy extracorporeal shock wave therapy? *Clin Interv Aging*. 2007;2:623-630.
34. Modena DAO, da Silva CN, Grecco C, et al. Extracorporeal shock wave: mechanisms of action and physiological aspects for cellulite, body shaping, and localized fat—systematic review. *J Cosmet Laser Ther*. 2017;19:314-319.
35. Knobloch K, Kraemer R. Extracorporeal shock wave therapy (ESWT) for the treatment of cellulite – A current metaanalysis. *Int J Surg*. 2015;24:210-217.
36. Luebberding S, Krueger N, Sadick NS. Cellulite: an evidence-based review. *Am J Clin Dermatol*. 2015;16:243-256.
37. Fritz K, Samková P, Salavastru C, Hudec J. A novel selective RF applicator for reducing thigh circumference: a clinical evaluation. *Dermatol Ther*. 2016;29:92-95.
38. Fritz K, Salavastru C. Ways of noninvasive facial skin tightening and fat reduction. *Facial Plast Surg*. 2016;32:276-282.
39. Fritz K, Bernardy J, Tiplica GS, Machovcova A. Efficacy of monopolar radiofrequency on skin collagen remodeling: a veterinary study: monopolar radiofrequency on skin collagen. *Dermatol Therapy*. 2015;28:122-125.
40. Lapidoth M, Halachmi S (Eds). *Radiofrequency in Cosmetic Dermatology* vol 2. Aesthet Dermatol Basel, Karger, 2015: 70-80. 10.1159/000368736
41. Fritz K, Salavastru C. Energy based devices: Radio frequency and high intensity focused ultra-sound chapter. In: Kautz G, ed. *Energy for the Skin*. Springer; 2020.
42. Fritz K, Salavastru C. Long-term follow-up on patients treated for abdominal fat using a selective contactless radiofrequency device. *J Cosmet Dermatol*. 2017;16:471-475.
43. Wanitphakdeedecha R, Sathaworawong A, Manuskiatti W, Sadick NS. Efficacy of multipolar radiofrequency with pulsed magnetic field therapy for the treatment of abdominal cellulite. *J Cosmet Laser Ther*. 2017;19:205-209.
44. Fritz K, Salavastru C, Gyurova M. Clinical evaluation of simultaneously applied monopolar radiofrequency and targeted pressure energy as a new method for non-invasive treatment of cellulite in post-pubertal women. *J Cosmet Dermatol*. 2018;17:361-364.
45. Rossi ABR, Vergnanini AL. Cellulite: a review. *J Eur Acad Dermatol Venereol*. 2000;14:251-262.
46. Peterson JD, Goldman MP. Laser, light, and energy devices for cellulite and lipodystrophy. *Clin Plast Surg*. 2011;38:463-474.
47. Jackson RF, Roche GC, Shanks SC. A double-blind, placebo-controlled randomized trial evaluating the ability of low-level laser therapy to improve the appearance of cellulite: LLLT improves the appearance of cellulite. *Lasers Surg Med*. 2013;45:141-147.
48. DiBernardo BE, Sasaki GH, Katz BE, Hunstad JP, Petti C, Burns AJ. A multicenter study for cellulite treatment using a 1440-nm nd:Yag wavelength laser with side-firing fiber. *Aesthet Surg J*. 2016;36:335-343.
49. Sadick N. Treatment for cellulite. *Int J Womens Dermatol*. 2018;5:68-72.
50. Cogorno WV. Body vectoring technique with Radiesse[®] for tightening of the abdomen, thighs, and brachial zone. *Clin Cosmet Investig Dermatol*. 2015;8:267-273.
51. Lapatina NG, Pavlenko T. Diluted calcium hydroxylapatite for skin tightening of the upper arms and abdomen. *J Drugs Dermatol*. 2017;16:900-906.
52. Mazzuco R. Subcision™ plus poly-l-lactic acid for the treatment of cellulite associated to flaccidity in the buttocks and thighs. *J Cosmet Dermatol*. 2020;19:1165-1171.
53. Sadick NS, Goldman MP, Liu G, et al. Collagenase clostridium histolyticum for the treatment of edematous fibrosclerotic panniculopathy (Cellulite): a randomized trial. *Dermatol Surg*. 2019;45:1047-1056.
54. Kaufman-Janette JA, Bass LS, Xiang Q, McLane MP, Kirby MT, Vijayan S. Efficacy, safety, and durability of response of collagenase clostridium histolyticum-aes for treating cellulite. *Plast Reconstr Surg Glob Open*. 2020;8:e3316.
55. Kaufman-Janette J, Joseph JH, Kaminer MS, et al. Collagenase clostridium histolyticum-aes for the treatment of cellulite in women: results from two phase 3 randomized, placebo-controlled trials. *Dermatol Surg*. 2021;47:649-656.
56. U.S. FDA Approves Qwo™ (collagenase clostridium histolyticum-aes), the first injectable treatment for cellulite. 2020. Available at <https://investor.endo.com/news-releases/news-release-details/us-fda-approves-qwotm-collagenase-clostridium-histolyticum-aes>. Accessed August 9, 2021.
57. Juhász M, Korta D, Mesinkovska NA. A review of the use of ultrasound for skin tightening, body contouring, and cellulite reduction in dermatology. *Dermatol Surg*. 2018;44:949-963.
58. Moravvej H, Akbari Z, Mohammadian S, Razzaghi Z. Focused ultrasound lipolysis in the treatment of abdominal cellulite: an open-label study. *J Lasers Med Sci*. 2015;6:102-105.
59. Kwon TR, Im S, Jang YJ, et al. Improved methods for evaluating pre-clinical and histological effects of subcutaneous fat reduction using high-intensity focused ultrasound in a porcine model. *Skin Res Technol*. 2017;23:194-201.
60. Solish N, Lin X, Axford-Gatley RA, Strangman NM, Kane M. A randomized, single blind, postmarketing study of multiple energy levels of high-intensity focused ultrasound for noninvasive body sculpting. *Dermatol Surg*. 2012;38:58-67.
61. Foster KW, Kouba DJ, Hayes J, et al. Reductions in thigh and infraumbilical circumference following treatment with a novel device combining ultrasound, suction, and massage. *J Drugs Dermatol*. 2008;7:113-115.
62. Suh DH, Choi JH, Lee SJ, Jeong K-H, Song KY, Shin MK. Comparative histometric analysis of the effects of high-intensity focused ultrasound and radiofrequency on skin. *J Cosmet Laser Ther*. 2015;17:230-236.

63. Kapoor R, Shome D, Ranjan A. Use of a novel combined radiofrequency and ultrasound device for lipolysis, skin tightening and cellulite treatment. *J Cosmet Laser Ther*. 2017;19:266-274.
64. Pianez LR, Custódio FS, Guidi RM, de Freitas JN, Sant'Ana E. Effectiveness of carboxytherapy in the treatment of cellulite in healthy women: a pilot study. *Clin Cosmet Investig Dermatol*. 2016;9:183-190.
65. Park JH, Wee SY, Chang J, et al. Carboxytherapy-induced fat loss is associated with VEGF-mediated vascularization. *Aesthetic Plast Surg*. 2018;42:1681-1688.
66. Lee GSK. Quality survey on efficacy of carboxytherapy for localized lipolysis. *J Cosmet Dermatol*. 2016;15:484-492.
67. Eldsouky F, Ebrahim HM. Evaluation and efficacy of carbon dioxide therapy (carboxytherapy) versus mesolipolysis in the treatment of cellulite. *J Cosmet Laser Ther*. 2018;20:307-312.
68. Resonic™ for cellulite reduction. Available at <https://www.resonic.com/cellulite-reduction/how-it-works>. Accessed on August 9, 2021.
69. Davis DS, Boen M, Fabi SG. Cellulite: patient selection and combination treatments for optimal results—a review and our experience. *Dermatol Surg*. 2019;45:1171-1184.
70. Lindgren A, Hui Austin A, Welsh KM. Specific use: cosmetics for body skin texture and cellulite treatment. In: Comstock J, Gold MH, eds. *Aesthetic Dermatology*. S. Karger AG; 2021;104-113.

How to cite this article: Arora G, Patil A, Hooshanginezhad Z, et al. Cellulite: Presentation and management. *J Cosmet Dermatol*. 2022;21:1393-1401. doi:[10.1111/jocd.14815](https://doi.org/10.1111/jocd.14815)