

# Evaluation of the effect of extracorporeal shock wave treatment on experimentally induced osteoarthritis in middle carpal joints of horses

David D. Frisbie, DVM, PhD; Christopher E. Kawcak, DVM, PhD; C. Wayne McIlwraith, BVSc, PhD

**Objective**—To assess the clinical, biochemical, and histologic effects of extracorporeal shock wave therapy (ESWT) in the treatment of horses with experimentally induced osteoarthritis (OA).

**Animals**—Twenty-four 2- to 3-year-old horses without evidence of lameness.

**Procedures**—OA was induced arthroscopically in 1 middle carpal joint of each horse. Fourteen days after induction of OA, horses were treated with a sham ESWT probe (placebo; n = 8), polysulfated glycosaminoglycan (PSGAG) administered IM every 4 days for 28 days as a positive control treatment (8), or ESWT administered on days 14 and 28 with a focused shock wave unit (8). Evaluations included clinical assessments of degree of lameness every 2 weeks and weekly synovial fluid analyses. Horses were euthanized 70 days after induction of OA, and gross pathologic and histologic examinations of cartilage and synovial membrane specimens were performed at necropsy. A generalized linear mixed model was used to compare outcomes among treatment groups.

**Results**—No adverse treatment-related events were detected in any horse. The degree of lameness in horses treated with ESWT improved significantly, compared with the degree of lameness in placebo- or PSGAG-treated horses. No disease-modifying effects were evident in results for synovial fluid, synovial membranes, or cartilage from the ESWT- or PSGAG-treated horses.

**Conclusions and Clinical Relevance**—Although a disease-modifying effect of ESWT was not detected, the significant clinical effect of ESWT suggested that this modality should be considered for treatment of horses with OA in combination with another modality that does affect the disease process. (*Am J Vet Res* 2009;70:449–454)

Treatment of horses for joint disease remains a major challenge in equine practice and has an economic impact on the racing industry. Various treatments exist, many of which are effective, but some horses remain refractory to standard treatment.

It has been suggested that ESWT may be an effective treatment for horses with joint disease, particularly horses that are refractory to standard treatments (eg, corticosteroid drugs). Little information has been published regarding the in vivo effects of shock wave therapy on joint tissue; however, a study<sup>1</sup> conducted in rabbits did not reveal any important safety concerns. Anecdotal<sup>2,3</sup> and case reports<sup>2,3</sup> exist, but to the authors' knowledge, no reports of controlled studies of ESWT in the treatment of horses with joint disease have been published. In dogs with OA, treatment with ESWT does not appear to yield a significant improvement in the degree of lameness, although it does appear to prevent deterioration, compared with the effects of no treatment.<sup>4</sup> In another study,<sup>3</sup> dogs with clinical OA of the hip joint

## ABBREVIATIONS

ESWT	Extracorporeal shock wave therapy
GAG	Glycosaminoglycan
OA	Osteoarthritis
PGE <sub>2</sub>	Prostaglandin E <sub>2</sub>
PSGAG	Polysulfated glycosaminoglycan

were treated with a radial pressure wave device, resulting in improved results of force plate analyses relative to pretreatment values.

The mechanism by which ESWT exerts its therapeutic effects in the treatment of animals with joint disease is unclear. The purpose of the study reported here was to assess the clinical, biochemical, and histologic effects of electrohydraulic-focused ESWT in the treatment of horses with experimentally induced OA. A secondary purpose was to investigate possible mechanisms of action by which ESWT yields any therapeutic benefits in joint tissues.

## Materials and Methods

**Animals**—Twenty-four 2- to 3-year-old horses that were free of lameness were used. Prior to inclusion, horses underwent a lameness examination and body

Received April 5, 2008.

Accepted July 11, 2008.

From the Equine Orthopaedic Research Center, Department of Clinical Sciences, College of Veterinary Medicine and Biomedical Sciences, Colorado State University, Fort Collins, CO 80523.

Address correspondence to Dr. Frisbie.

condition assessment. In addition, radiographic views of the carpal joints, range of motion (flexion) of the carpal joints, and evidence of joint effusion were assessed to ensure that all measurements were within reference limits. The study protocol was approved by the Colorado State University Animal Care and Use Committee.

**Experimental design**—Horses were randomly assigned (by means of numbers in an envelope) to 1 of 3 treatment groups: placebo ( $n = 8$ ), ESWT<sup>a</sup> (8), or PSGAG.<sup>b</sup> A middle carpal joint of each horse was also randomly assigned to receive a sham operation (control joint); the opposite joint was assigned to undergo experimental induction of OA (OA joint). The day of surgery was designated as day 0, and the study was terminated on day 70 (ie, 10 weeks after surgery).

**Experimental induction of OA**—After a minimum 14-day acclimatization period that included training to safely use the high-speed treadmill as well as equilibration to new environmental factors, each horse underwent bilateral arthroscopic surgery of both middle carpal joints to ensure that there were no preexisting abnormalities. During this procedure, an OA fragment was created in 1 middle carpal joint as described elsewhere.<sup>6</sup> Briefly, the fragment was generated by use of an 8-mm curved osteotome directed perpendicular to the articular cartilage surface of the radial carpal bone at the level of the medial synovial plica. The fragment was allowed to remain adhered to the joint capsule proximally. A motorized arthroscopic burr was used to debride the exposed subchondral bone between the fragment and the radial carpal bone.<sup>6</sup> A 15-mm-wide defect bed for the 8-mm-wide fragment was created, and the debris was not actively flushed from the joint so that OA would be induced. In the other (control) joint, the same protocol was followed with the exception that an OA fragment was not created. The arthroscopic portals in both joints were closed with 2-0 nylon suture in a simple interrupted or cruciate pattern.

The forelimbs of each horse were bandaged, and horses were allowed to recover from anesthesia and surgery. Each horse received phenylbutazone (2 g, PO, q 24 h) for 5 days after surgery. Bandages were changed every 3 to 5 days and maintained for 2 weeks. Sutures were removed 10 days after surgery.

**Exercise**—After surgery, horses were housed in a stall (3.65 × 3.65 m) unless otherwise indicated. Beginning on day 15, horses were exercised on a high-speed treadmill 5 d/wk until the end of the study. Each day, the horses were trotted (16 to 19 km/h) for 2 minutes, galloped (approx 32 km/h) for 2 minutes, and again trotted (16 to 19 km/h) for 2 minutes to simulate the strenuous exercise of race training.

**Treatments**—Treatment began on day 14 after surgical induction of OA for all horses. A No. 40 blade was used to clip the hair over the carpal joints of horses in all treatment groups so that treatment received could not be ascertained by the appearance of the horse. Horses assigned to receive ESWT (placebo or actual treatment) were also sedated IV as needed by use of a combination of xylazine (0.5 mg/kg) and butorphanol (0.02 mg/kg). Horses assigned to receive PSGAG were not sedated.

After sedation of horses in the placebo group, a shield of air cellular cushioning material<sup>c</sup> was placed over the probe head (focal point at 12 mm) during the sham ESWT of the OA joints to block the shock waves. The first treatment (on day 14) consisted of 2,000 pulses with energy setting E4 (0.14 mJ/mm<sup>2</sup>). A total of 8 areas (4 areas on the proximal and 4 areas on the distal aspect of the capsule of the middle carpal joint) were exposed to 200 pulses each. The remaining 400 pulses were delivered over the area of the OA fragment. On day 28 of the study, a second treatment consisting of a total of 1,500 pulses with energy setting E6 (0.15 mJ/mm<sup>2</sup>) was administered. Two hundred pulses were delivered to a total of 6 areas (3 areas on the proximal aspect and 3 areas on the distal aspect of the capsule of the middle carpal joint) and 300 pulses over the area of the OA fragment. This treatment protocol was developed on the basis of the authors' clinical experience and opinions from other users as conveyed via the manufacturer.

Horses in the ESWT group underwent a similar treatment protocol (1 ESWT treatment on day 14 and another on day 28), with the exception that the probe head was not shielded. Horses in the PSGAG group received IM injections of 500 mg of PSGAG in alternating sites of the neck every 4 days for 28 days, starting on day 14.

**Assessment of clinical outcomes**—For each horse, clinical examinations of both forelimbs were performed every 14 days from prior to day 0 (baseline) throughout the study period. Lameness was graded on a scale of 0 to 5, with 0 representing clinically normal gait and 5 representing severe lameness.<sup>7</sup> After lameness grading, 1 carpal joint was flexed and then the horse was trotted to identify any increase in pain that resulted from manipulation and stress concentrated at the middle carpal joint. The response to flexion was graded on a scale of 0 to 4, with 0 representing no response and 4 representing a severe response. The lameness grading procedure was duplicated for the ipsilateral carpal joint.

Carpal joints were palpated to detect effusion in the middle carpal joint, and the extent of the effusion was graded on a scale of 0 to 4 (0 = typical fluid volume and 4 = severe increase in fluid volume). All clinical outcome parameters were assessed by a board-certified large animal surgeon (a specialist in equine lameness), who was unaware of treatment assignments. In some horses, bilateral forelimb lameness was detected through clinical experience and by turning the horse in either direction, and no diagnostic intra-articular anesthesia was used in these horses.

**Synovial fluid**—Beginning on day 0 and until the end of the study, a synovial fluid sample was aseptically aspirated from each middle carpal joint of each horse on a weekly basis. The timing of these collections occurred at a similar period after feeding and before other procedures such as exercise or surgery. Synovial fluid (2 to 4 mL) was directly aspirated from each joint space by use of a 20-gauge needle and a syringe. Samples were placed in tubes containing EDTA for routine synovial fluid analysis or stored at -80°C for biochemical and biomarker protein analysis.

Conventional analysis of synovial fluid included assessment of color, clarity, total protein concentration, total and differential WBC counts, and mucin clot formation. Synovial fluid color, clarity, mucin content, and blood contamination were evaluated subjectively. Color of synovial fluid was graded on a scale of 1 to 5 (1 = yellow; 2 = colorless; 3 = straw colored; 4 = orange; and 5 = red). Clarity was graded on a scale of 1 to 3 (1 = clear; 2 = hazy; and 3 = cloudy). Mucin content was graded on a scale of 1 to 3 (1 = good; 2 = fair; and 3 = poor). Blood contamination of synovial fluid samples was graded as 1 or 2 (1 = samples with no blood contamination and 2 = samples with blood contamination).<sup>6</sup> Total protein and WBC concentrations were determined via refractometry and use of an automated cell counter, respectively. Smears of synovial fluid were examined cytologically to determine the differential WBC count. The concentration of PGE<sub>2</sub> in synovial fluid was estimated by use of a commercially available, competitive, highly sensitive ELISA<sup>d</sup> as directed by the manufacturer. The concentration of GAG in synovial fluid was assessed by means of a modified dye-binding assay.<sup>8</sup>

**Bone assessment**—During the acclimatization period prior to arthroscopic surgery and after euthanasia, computed tomographic osteoabsorptiometry was performed on both carpal joints of each horse. Calcein (20 mg/kg, IV) and oxytetracycline (25 mg/kg, IV) were administered to each horse to aid in the evaluation of bone remodeling and microdamage. Results of that evaluation will be described in a separate report.

**Gross evaluation of joints**—At the end of the study, all horses were euthanized with an overdose of sodium pentobarbital so that gross and histologic data could be obtained. For each horse, a necropsy was performed, during which both middle carpal joints were specifically examined for degree and location of articular cartilage fibrillation or erosion. A scale of 0 to 4 (0 = no pathologic change and 4 = severe pathologic change) was used to subjectively grade degrees of total, partial-, and full-thickness cartilage erosion as well as synovial membrane hemorrhage. A score for total pathologic change was also calculated via summation of the scores for articular cartilage erosion and synovial membrane hemorrhage.

**Histologic examinations**—At necropsy, specimens of synovial membrane and joint capsule were collected from the region dorsal to the OA fragment and placed in neutral-buffered 10% formalin. Fixed tissues were sectioned at a thickness of 5  $\mu$ m, and sections were routinely stained with H&E. Sections of synovial membrane and joint capsule were examined for cellular infiltration, synovial intimal hyperplasia, subintimal edema, subintimal fibrosis, and subintimal vascularity.<sup>6</sup> Each variable was graded on a scale of 0 to 4, with 0 representing no pathologic change and 4 representing the most severe change. A score of total pathologic change was also calculated for synovial membrane specimens.

Pieces of articular cartilage (5 mm<sup>2</sup>) were obtained from each joint (Figure 1). Collection locations were chosen to represent an area directly adjacent to the OA fragment, a portion of the opposing articulating surface (third carpal bone), and a remote location (fourth car-

pal bone). Cartilage specimens were stored in neutral-buffered 10% formalin for 7 days and then processed routinely to obtain 5- $\mu$ m-thick sections for histologic examination. Half of the sections were stained with H&E, and the remainder was stained with safranin-O fast-green stain.

Sections stained with H&E were evaluated for articular cartilage fibrillation, chondrocyte necrosis, chondrone formation (chondrocyte division within a lacuna), and focal loss of cells.<sup>6</sup> Numeric values ranging from 0 to 4 were assigned to each variable, with 0 representing no pathologic change and 4 representing the most severe change.

Sections of articular cartilage processed with safranin-O fast-green stain were evaluated for intensity of staining in the tangential, intermediate, radiate territorial, and radiate interterritorial zones.<sup>6</sup> Numeric values ranging from 0 to 4 were assigned to each variable, with 0 indicating no stain uptake and 4 indicating histologically normal stain uptake. All histologic examinations were performed by an evaluator who was unaware of treatment assignments.

To estimate proteoglycan content in articular cartilage, the total concentration of GAG in articular cartilage was measured by use of a 9-dimethyl methylene blue technique.<sup>6</sup> Pieces of articular cartilage were aseptically obtained from a remote site within each joint (Figure 1), and each piece was stored at -80°C prior to additional processing and analysis. Specimens were processed in duplicate.

**Statistical analysis**—Data were analyzed by means of a generalized linear mixed model.<sup>e</sup> Treatment, existence of OA, and, when present, repeated measures

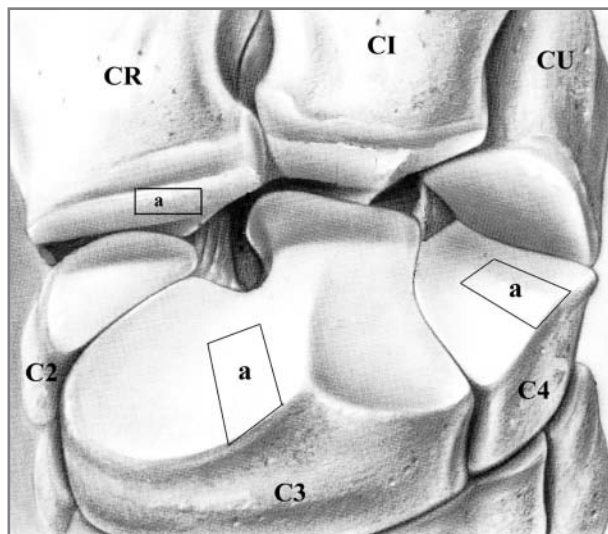


Figure 1—Illustration of the sites from which articular cartilage was obtained from a middle carpal joint for histologic evaluation of the effects of treatment with ESWT and PSGAG in horses. Collection locations were chosen to represent an area directly adjacent to an experimentally induced OA fragment, a portion of the opposing articulating surface (third carpal bone), and a remote location (fourth carpal bone). Specimens for histologic evaluation were obtained from the areas marked "a." Specimens for biochemical evaluation were obtained from the intermediate carpal bone (CI). CR = Radial carpal bone. CU = Ulnar carpal bone. C2 = Second carpal bone. C3 = Third carpal bone. C4 = Fourth carpal bone.

were considered as main effects. All interactions among main effect variables were also evaluated. The potential effect of horse on the outcome variables was controlled via the introduction of a random effect for horse. When supported by results of the generalized linear model, individual comparisons among the main effect or interaction variables were made by means of least squares means analysis. A value of  $P < 0.05$  was considered significant for all analyses. Results are reported as least squares mean  $\pm$  SEM.

## Results

**Clinical assessments**—Mild lameness was typically evident in all limbs of horses in which OA was induced (mean  $\pm$  SEM lameness score,  $2.20 \pm 0.11$ ). This mean lameness score differed significantly ( $P < 0.01$ ) from the baseline value measured before OA was induced ( $0.25 \pm 0.11$ ), and the difference persisted throughout the study period. The mean lameness score for OA-affected limbs of the ESWT-treated horses ( $1.25 \pm 0.19$ ) was significantly ( $P < 0.01$ ) lower at 14 days after the first treatment, which was the first measurement point (day 28), compared with the score for the OA-affected limbs of the placebo-treated horses ( $2.13 \pm 0.19$ ). This significant reduction in the degree of lameness between ESWT- and placebo-treated horses was maintained for the remaining study period (a total of 70 days). At the conclusion of the study (day 70), significant improvement in mean lameness score was also evident in the OA-affected limbs of ESWT- versus PSGAG-treated horses (Figure 2). On the other hand, no significant differences in degrees of lameness were detected at any point of the study when lameness scores for placebo-treated horses were compared with those of PSGAG-treated horses.

The mean score for response to carpal flexion was also significantly ( $P < 0.01$ ) increased in OA-affected ( $1.16 \pm 0.06$ ) versus sham-operated control ( $0.19 \pm 0.06$ ) limbs in all 28 horses after OA was induced. A nonsignificant ( $P = 0.06$ ) improvement in flexion was evident between OA-affected limbs when the mean score for ESWT-treated limbs ( $1.25 \pm 0.10$ ) was compared with that for placebo-treated limbs ( $1.52 \pm 0.10$ ). Conversely, when scores from the entire study period were averaged, OA-affected limbs of PSGAG-treated horses were significantly ( $P < 0.01$ ) more responsive to carpal flexion (mean score,  $2.05 \pm 0.10$ ) than OA-affected limbs of placebo-treated horses ( $1.52 \pm 0.10$ ). On day 70, the response to carpal flexion was still improved in OA-affected limbs of ESWT-treated horses, compared with the response in placebo- and ESWT-treated horses; however, there was no difference in carpal flexion scores between placebo- and PSGAG-treated horses at this point (Figure 3). A significant ( $P < 0.01$ ) increase in mean synovial effusion score was evident in OA-affected ( $1.45 \pm 0.07$ ) versus control limbs ( $0.33 \pm 0.07$ ) during the period after OA was induced.

**Synovial fluid**—Results of conventional synovial fluid analysis indicated no significant differences in synovial fluid color, clarity, mucin clot formation, or WBC counts for any comparisons. Joints in the OA-affected limbs ( $2.72 \pm 0.08$  g/dL) had a significantly ( $P < 0.01$ )

greater mean total protein concentration, compared with those of control limbs ( $2.33 \pm 0.08$  g/dL). Although not supported by results of the generalized linear mixed model ( $P = 0.18$ ), when individual comparisons by treatment group and presence of OA were made, the synovial fluid from OA joints of horses in the ESWT and PSGAG groups contained a lower total protein concentration than did OA joints of horses in the placebo group when values were averaged after treatment (Figure 4). In addition, the mean concentration of PGE<sub>2</sub> in synovial fluid throughout the study was significantly ( $P < 0.01$ ) higher in OA joints ( $107.25 \pm 1.04$  pg/mL) after OA was induced, compared with the value for control joints ( $62.19 \pm 1.04$  pg/mL). No

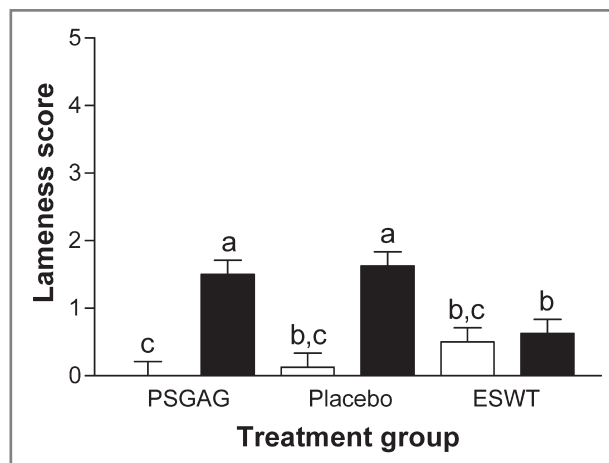


Figure 2—Mean  $\pm$  SEM lameness scores for forelimbs of 24 horses in which OA was (black bars; 24 joints) or was not (white bars; 24) experimentally induced in middle carpal joints and that were subsequently treated with placebo (n = 8 horses), ESWT (8), and PSGAG (8) 14 days after surgery, as measured 70 days after surgery. Lameness was graded on a scale of 0 to 5, with 0 representing clinically normal gait and 5 representing severe lameness. <sup>a-c</sup>Different letters indicate a significant ( $P < 0.05$ ) difference between treatment groups.

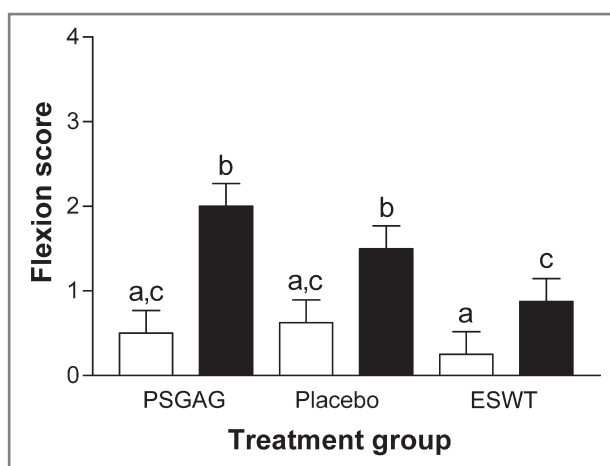


Figure 3—Mean  $\pm$  SEM flexion scores for middle carpal joints of 24 horses in which OA was (black bars; 24 joints) or was not (white bars; 24) experimentally induced and that were subsequently treated with placebo (n = 8 horses), ESWT (8), and PSGAG (8) 14 days after surgery, as measured 70 days after surgery. Response to flexion was graded on a scale of 0 to 4, with 0 representing no response and 4 representing a severe response. See Figure 2 for remainder of key.



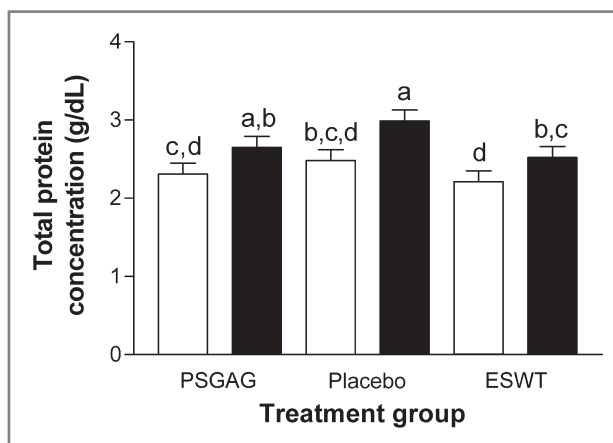


Figure 4—Mean  $\pm$  SEM total protein concentration for middle carpal joints of 24 horses in which OA was (black bars; 24 joints) or was not (white bars; 24) experimentally induced and that were subsequently treated with placebo ( $n = 8$  horses), ESWT (8), and PSGAG (8) 14 days after surgery, as measured 70 days after surgery. See Figure 2 for remainder of key.

other groups differed with respect to mean PGE<sub>2</sub> concentration in synovial fluid.

A significant ( $P < 0.01$ ) increase in mean synovial fluid GAG concentration was detected in OA joints ( $117.2 \pm 1.01 \mu\text{g/mL}$ ), compared with that of control joints ( $111.50 \pm 1.01 \mu\text{g/mL}$ ). No other groups differed with respect to mean synovial fluid GAG concentration.

**Gross pathologic evaluation**—Mean scores for degree of full-thickness articular cartilage fibrillation (not partial thickness), hemorrhage, and total pathologic change were significantly ( $P < 0.01$ ) higher in OA joints (score for total pathologic change,  $5.38 \pm 0.40$ ), compared with the value for control joints ( $1.13 \pm 0.40$ ). No significant treatment effects were evident in any other gross pathologic score or comparison.

**Histologic examinations**—The mean score for total pathologic change in H&E-stained synovial membrane tissues from OA joints ( $7.04 \pm 0.48$ ) was significantly ( $P = 0.01$ ) higher than the score for control joints ( $5.50 \pm 0.48$ ). No significant treatment effects were evident for any other synovial membrane score or comparison.

Representative articular cartilage specimens from the radial and third and fourth carpal bones stained with H&E revealed a significantly (all  $P < 0.01$ ) higher amount of articular cartilage fibrillation, chondrocyte necrosis, chondrone formation, and focal cell loss in OA joints (total score,  $2.88 \pm 0.26$ ) versus control joints ( $1.60 \pm 0.26$ ). No significant treatment effects were evident in any other articular cartilage score or comparison, nor were any differences apparent among groups when sections of articular cartilage were processed with safranin-O fast-green stain. The concentration of GAG in articular cartilage was not altered by induction of OA or treatment.

## Discussion

As expected, experimental induction of OA in a middle carpal joint of horses resulted in significant

changes in clinical, gross, histologic, and biochemical measurements, compared with respective values in the control joint of the same horses. Treatment with ESWT 14 and 28 days after OA was induced yielded significant changes for many variables in affected limbs, compared with values for respective variables in placebo- and PSGAG-treated OA-affected limbs. Furthermore, the beneficial effects lasted for 42 days after the last treatment, which was the longest interval measured.

The first beneficial effects were evident within 14 days after the first treatment (28 days after experimental induction of OA), which was the first time they were assessed following treatment. An analgesic effect of ESWT has been reported,<sup>9,10</sup> but this analgesic effect persists for 2 to 3 days and does not explain the reduction in clinical signs of lameness that were evident beginning 14 days after treatment. The origin of the apparent clinical effect could not be definitively determined.<sup>11</sup>

Release of substance P, an endogenous analgesic, may be induced via ESWT,<sup>12</sup> but that hypothesis was not investigated in the present study. Results of our study did not provide any direct explanation for the improvement in lameness score after ESWT, although improvement in the response to carpal flexion provided additional confirmation of the effect of ESWT on reducing clinical signs of OA. The total protein concentration of synovial fluid within OA joints of ESWT-treated horses appeared to decrease, thereby suggesting that a decrease in synovitis could be in part responsible for the reduced clinical signs of lameness. Although that decrease was not significant in the generalized linear model, this comparison was undertaken because the comparison was planned a priori.

Whereas mean histologic scores for pathologic change in synovial membrane tissues appeared to be lower in ESWT- versus placebo-treated horses, they were not significantly different. On the other hand, no significant change in synovial fluid PGE<sub>2</sub> concentration was evident, suggesting that the arachidonic acid pathway was not involved in the reduction of clinical signs of OA, although such effects have been detected in other animal species.<sup>12–15</sup> Consequently, we were unable to make any definitive conclusion regarding the exact mechanism through which ESWT exerts its effects. Results of the present study concurred with those of other studies<sup>4,5</sup> of dogs with clinical OA of hip and stifle joints, in which beneficial effects of ESWT were detected.

In the study reported here, the improvement in clinical signs of OA that was evident after ESWT was not supported by any evidence of disease-modifying effects at the gross pathologic, histologic, or biochemical level. In another study<sup>16</sup> involving rats, ESWT improved neovascularization and recruitment of mesenchymal progenitor cells and increased production of transforming growth factor- $\beta$ , all of which are mechanisms that may yield disease-modifying effects. Additional research into the mechanism of improvement or potential disease-modifying effects associated with ESWT is required.

- a. VersaTron, Sanuwave Inc, Alpharetta, Ga.
- b. Adequan IA, Luitpold Pharmaceuticals Inc, Shirley, NY.
- c. Bubble wrap, Sealed Air Corp, Elmwood Park, NJ.

- d. PGE<sub>2</sub> ELISA, Assay Design, Ann Arbor, Mich.
- e. Proc GLM, SAS, version 9.1, SAS Institute, Cary, NC.

---

## References

1. Väterlein N, Lussenhop S, Hahn M, et al. The effect of extracorporeal shock waves on joint cartilage—an in vivo study in rabbits. *Arch Orthop Trauma Surg* 2000;120:403–406.
2. Revenaugh MS. Extracorporeal shock wave therapy for treatment of osteoarthritis in the horse: clinical applications. *Vet Clin North Am Equine Pract* 2005;21:609–625, vi.
3. McCarroll GD, McClure S. Extracorporeal shock wave therapy for treatment of osteoarthritis of the tarsometatarsal and distal intertarsal joints of the horse, in *Proceedings. 46th Annu Meet Am Assoc Equine Pract* 2000;200–201.
4. Dahlberg J, Fitch G, Evans RB, et al. The evaluation of extracorporeal shockwave therapy in naturally occurring osteoarthritis of the stifle joint in dogs. *Vet Comp Orthop Traumatol* 2005;18:147–152.
5. Mueller M, Bockstahler B, Skalicky M, et al. Effects of radial shockwave therapy on the limb function of dogs with hip osteoarthritis. *Vet Rec* 2007;160:762–765.
6. Frisbie DD, Ghivizzani SC, Robbins PD, et al. Treatment of experimental equine osteoarthritis by in vivo delivery of the equine interleukin-1 receptor antagonist gene. *Gene Ther* 2002;9:12–20.
7. Anonymous. Definition and classification of lameness. In: *Guide for veterinary service and judging of equestrian events*. Lexington, Ky: American Association of Equine Practitioners, 1991;19.
8. Farndale RW, Buttle DJ, Barrett AJ. Improved quantitation and discrimination of sulphated glycosaminoglycans by use of dimethylmethylene blue. *Biochim Biophys Acta* 1986;883:173–177.
9. Dahlberg JA, McClure SR, Evans RB, et al. Force platform evaluation of lameness severity following extracorporeal shock wave therapy in horses with unilateral forelimb lameness. *J Am Vet Med Assoc* 2006;229:100–103.
10. McClure SR, Sonea IM, Evans RB, et al. Evaluation of analgesia resulting from extracorporeal shock wave therapy and radial pressure wave therapy in the limbs of horses and sheep. *Am J Vet Res* 2005;66:1702–1708.
11. Abed JM, McClure SR, Yaeger MJ, et al. Immunohistochemical evaluation of substance P and calcitonin gene-related peptide in skin and periosteum after extracorporeal shock wave therapy and radial pressure wave therapy in sheep. *Am J Vet Res* 2007;68:323–328.
12. Maier M, Averbeck B, Milz S, et al. Substance P and prostaglandin E2 release after shock wave application to the rabbit femur. *Clin Orthop Relat Res* 2003;237–245.
13. Gibson KT, Hodge H, Whittem T. Inflammatory mediators in equine synovial fluid. *Aust Vet J* 1996;73:148–151.
14. Stowater JL, Kirker-Head CA, Jakowski RM. Osteochondrosis in the lateral femoral condyles of a horse. *Vet Radiol* 1986;27:115–117.
15. Trumble TN, Billingham RC, McIlwraith CW. Correlation of prostaglandin E2 concentrations in synovial fluid with ground reaction forces and clinical variables for pain or inflammation in dogs with osteoarthritis induced by transection of the cranial cruciate ligament. *Am J Vet Res* 2004;65:1269–1275.
16. Chen Y-J, Wurtz T, Wang C-J, et al. Recruitment of mesenchymal stem cells and expression of TGF-β1 and VEGF in the early stage of shock wave-promoted bone regeneration of segmental defect in rats. *J Orthop Res* 2005;22:526–534.